

Long-term outcome of esophageal myotomy for achalasia

Jun-Feng Liu, Jun Zhang, Zi-Qiang Tian, Qi-Zhang Wang, Bao-Qing Li, Fu-Shun Wang, Fu-Min Cao, Yue-Feng Zhang, Yong Li, Zhao Fan, Jian-Jing Han, Hui Liu

Jun-Feng Liu, Zi-Qiang Tian, Qi-Zhang Wang, Bao-Qing Li, Fu-Shun Wang, Fu-Min Cao, Yue-Feng Zhang, Yong Li, Zhao Fan, Jian-Jing Han, Hui Liu, Department of Thoracic Surgery, Fourth Hospital, Hebei Medical University, Shijiazhuang 050011, Hebei Province, China

Jun Zhang, Department of Surgery, Shenzhou City Hospital, Shenzhou 052860, Hebei Province, China

Correspondence to: Jun-Feng Liu, Department of Thoracic Surgery, Fourth Hospital, Hebei Medical University, 12 Jiankang Road, Shijiazhuang 050011, Hebei Province, China. liujf@heinfo.net

Telephone: +86-311-6033941 **Fax:** +86-311-6077634

Received: 2003-06-21 **Accepted:** 2003-07-24

Abstract

AIM: Modified Heller's myotomy is still the first choice for achalasia and the assessment of surgical outcomes is usually made based on the subjective sensation of patients. This study was to objectively assess the long-term outcomes of esophageal myotomy for achalasia using esophageal manometry, 24-hour pH monitoring, esophageal scintigraphy and fiberoptic esophagoscopy.

METHODS: From February 1979 to October 2000, 176 patients with achalasia underwent modified Heller's myotomy, including esophageal myotomy alone in 146 patients, myotomy in combination with Gallone or Dor antireflux procedure in 22 and 8 patients, respectively. Clinical score, pressure of the lower esophageal sphincter (LES), esophageal clearance rate and gastroesophageal reflux were determined before and 1 to 22 years after surgery.

RESULTS: After a median follow-up of 14 years, 84.5% of patients had a good or excellent relief of symptoms, and clinical scores as well as resting pressures of the esophageal body and LES were reduced compared with preoperative values ($P < 0.001$). However, there was no significant difference in DeMeester score between pre- and postoperative patients ($P = 0.51$). Esophageal transit was improved in postoperative patients, but still slower than that in normal controls. The incidence of gastroesophageal reflux in patients who underwent esophageal myotomy alone was 63.6% compared to 27.3% in those who underwent myotomy and antireflux procedure ($P = 0.087$). Three (1.7%) patients were complicated with esophageal cancer after surgery.

CONCLUSION: Esophageal myotomy for achalasia can reduce the resting pressures of the esophageal body and LES and improve esophageal transit and dysphagia. Myotomy in combination with antireflux procedure can prevent gastroesophageal reflux to a certain extent, but further randomized studies should be carried out to demonstrate its efficacy.

Liu JF, Zhang J, Tian ZQ, Wang QZ, Li BQ, Wang FS, Cao FM, Zhang YF, Li Y, Fan Z, Han JJ, Liu H. Long-term outcome of esophageal myotomy for achalasia. *World J Gastroenterol* 2004; 10(2): 287-291

<http://www.wjgnet.com/1007-9327/10/287.asp>

INTRODUCTION

Achalasia is an esophageal motility disorder characterized by failure of lower esophageal sphincter (LES) to relax with swallowing and by the absence of esophageal peristalsis. Up to now, surgical treatment is still the first choice for the disease although dilatation and medication have been reported extensively^[1-5]. Because pathophysiological changes of achalasia could not be rectified by any measures, the treatment usually aims at the reduction of LES pressure in order to increase esophageal transit and relieve dysphagia^[6].

The outcomes of myotomy for achalasia have been assessed usually according to the subjective sensation of patients in other studies^[7], which lack objective criteria. Until now, there have been no reports about the objective evaluation on long-term outcomes of Heller's myotomy for achalasia in a large group of patients in China. The aim of this study was to objectively evaluate the long-term outcomes of Heller's myotomy for achalasia by 24-hour pH monitoring, esophageal manometry, esophageal scintigraphy and esophagoscopy.

MATERIALS AND METHODS

General materials

From February 1979 to October 2000, 176 patients underwent modified Heller's myotomy for achalasia at the Department of Thoracic Surgery, Fourth Hospital, Hebei Medical University. There were 78 men and 98 women, ranging from 8 to 62 years (mean 32.9 years). All patients (100%) had varying extent of dysphagia for a mean of 4.8 years (range 2 months to 37 years) before operation. One hundred and thirteen (64.2%) patients had vomiting, 54 (30.7%) regurgitation at night, 8 (4.5%) chest pain or substernal discomfort and 2 (1.1%) heartburn. Symptoms were evaluated by a clinical scoring system proposed by Eckardt *et al*^[8], in which a sum of the individual scores of three major symptoms including dysphagia, heartburn and chest pain was calculated. Each of these symptoms was graded as followings: 0, absent; 1, occasional; 2 daily; 3, with each meal. Therefore, the highest score was 9.

Pre-operative examination

Before surgery, esophagography was performed for all patients, esophagoscopy (Olympus GIF 100) for 114, esophageal manometry (Synectics Medical, Stockholm, Sweden) for 50, 24-hour esophageal pH monitoring (Synectics Medical, Stockholm, Sweden) for 12, esophageal scintigraphy as previously described^[9] for 12 patients and 12 normal subjects as controls. Existence of gastroesophageal reflux was defined if a DeMeester score was more than 14.72 by 24-hour esophageal pH monitoring.

Surgery

Myotomy was performed from 5 cm above the esophagogastric junction to 1.5 cm distal to the esophagogastric junction for all of the 176 patients. As an antireflux procedure, Gallone operation^[10] was added for 22 patients and Dor operation^[11] for 8 patients. Thus, 146 patients underwent esophageal myotomy only, and 30 patients underwent combined esophageal myotomy and antireflux procedure in the present study.

Follow-up study

Fifty-eight patients were followed up from 1 year to 22 years after surgery, with a median follow-up of 14 years. The patients were inquired for dysphagia, heartburn and chest pain. Clinical scores were calculated according to Eckardt *et al*^[8] and compared with preoperative values. According to the method described by Devaney *et al*^[12], the efficacy of operation was graded as excellent (completely asymptomatic), good (mild symptoms requiring no treatment), fair (symptoms requiring occasional treatment such as dilatation or anti-diarrhea medication), and poor (symptoms requiring regular treatment). Postoperatively, esophageal manometry was performed for 30 patients, 24-hour pH monitoring for 22, esophageal scintigraphy for 42, and esophagoscopy for 15.

Statistical analysis

Data on clinical scores, resting pressures of the esophageal body and LES, and DeMeester scores were expressed as mean±SD, and analysed with Student's *t* test. The incidence of gastroesophageal reflux and esophagitis was assessed with Chi-square test. Statistical analyses were performed using a SPSS 10.0 software package, and the differences were considered as significant if $P \leq 0.05$.

RESULTS

In the present study, 84.5% (49/58) of patients had a good or excellent relief of dysphagia after a median follow-up of 14 years. Table 1 shows pre- and post-operative clinical scores, resting pressures of the esophageal body and LES, and DeMeester scores. Clinical scores and resting pressures of the esophageal body and LES were significantly reduced after Heller's myotomy ($P < 0.001$). After a long-term follow-up study, both clinical scores and LES pressures still remained lower than preoperative values, but had a trend of elevation

with the lapse of postoperative time (Figures 1 and 2). There were no significant differences in DeMeester score between pre- and post-operative patients ($P = 0.512$). DeMeester scores were above normal value in 33.3% (4/12) of preoperative patients, and in 45.5% (10/22) of postoperative patients ($P = 0.717$). In contrast, esophagitis was detected with esophagoscopy in 21.9% (25/114) of the patients before surgery and in 46.7% (7/15) after surgery ($P = 0.054$). Compared with preoperative patients, the esophageal clearance rate was improved in postoperative patients, but did not reach normal until the fifth minute after swallowing of isotope-labeled semi-liquid food (Table 2).

In group of esophageal myotomy with anti-reflux procedure, clinical scores were similar to those in group of esophageal myotomy alone ($P = 0.27$). Also, there was no significant difference in objective parameters including LES resting pressure and DeMeester score between the 2 groups ($P > 0.05$) (Table 3). Twenty-four-hour esophageal pH monitoring showed that the incidence of gastroesophageal reflux in patients undergoing esophageal myotomy with anti-reflux procedure was 27.3% (3/11) compared to 63.6% (7/11) in those undergoing esophageal myotomy only ($P = 0.087$).

Four patients were found to have varying extents of resumption of esophageal peristalsis by esophageal manometry at 20 months, 7, 15 and 20 years after esophageal myotomy, respectively (Figure 3). Three (1.7%) patients underwent re-operation, of whom 2 underwent myotomy again at 1 year and 4 years after surgery respectively for severe dysphagia due to scar formation around abdominal segment of the esophagus, and the remaining 1 underwent resection of the lower third of the esophagus at the third postoperative year due to repeated bleeding resulted from gastroesophageal reflux. Squamous cell carcinoma occurred in 3 (1.7%) patients at 6, 17 and 18 years after Heller's myotomy, respectively, and esophagectomy was performed for these patients.

Table 1 Objective and subjective parameters from patients with achalasia before and after Heller's myotomy

	Before surgery		After surgery		<i>t</i>	<i>P</i>
	<i>n</i>	mean±SD	<i>n</i>	mean±SD		
Clinical score	176	4.11±0.93	58	1.84±1.26	14.66	0.000
RP of the LES (cm H ₂ O)	50	31.14±10.54	30	18.05±8.90	5.76	0.000
RP of the EB (cm H ₂ O)	50	13.66±5.49	30	4.96±4.86	7.15	0.000
DeMeester score	12	33.87±54.2	22	49.75±73.4	0.663	0.512

RP=resting pressure, EB=esophageal body.

Table 2 Esophageal clearance rates for pre- and post-myotomy patients and normal controls (mean±SD%)

<i>n</i>	Times after isotope labeled semi-liquid meal intaken				
	5 th second	1 st minute	2 nd minute	5 th minute	
Normal controls	12	91.7±1.4	92.5±1.9	92.8±2.1	93.0±2.5
Pre-myotomy pts	12	7.5±2.1 ^a	40.4±28.2 ^a	45.5±30.1 ^a	50.5±35.5 ^a
Post-myotomy pts	42	33.7±8.8 ^b	80.2±19.1 ^c	85.4±12.2 ^c	94.4±5.1

^a $P < 0.01$ vs normal controls and post-myotomy patients, ^b $P < 0.01$ vs normal controls, ^c $P < 0.05$ vs normal controls.

Table 3 Subjective and objective parameters from patients who underwent Heller's myotomy alone and in combination with antireflux procedure

	Heller alone		Heller+antireflux		<i>t</i>	<i>P</i>
	<i>n</i>	mean±SD	<i>n</i>	mean±SD		
Clinical score	47	1.79±1.19	11	2.27±1.62	1.11	0.27
LES RP(cm H ₂ O)	25	18.4±9.80	5	16.6±3.23	0.44	0.66
DeMeester score	11	44.4±38.5	11	55.1±29.3	0.34	0.74

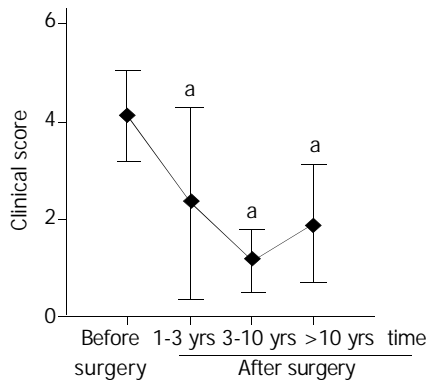


Figure 1 Clinical scores before and at various intervals after Heller's myotomy. Data were expressed as mean±SD. ^aP<0.001 vs before surgery.

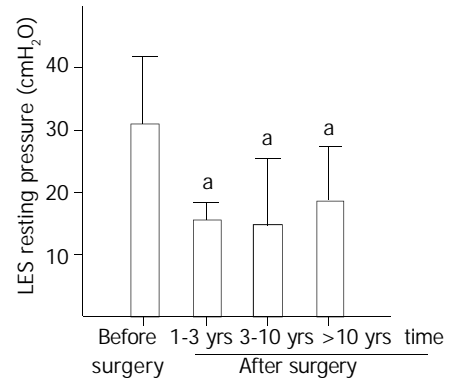


Figure 2 Lower esophageal sphincter (LES) pressure before and at various times after Heller's myotomy. Data were expressed as mean±SD. ^aP<0.001 vs before surgery.

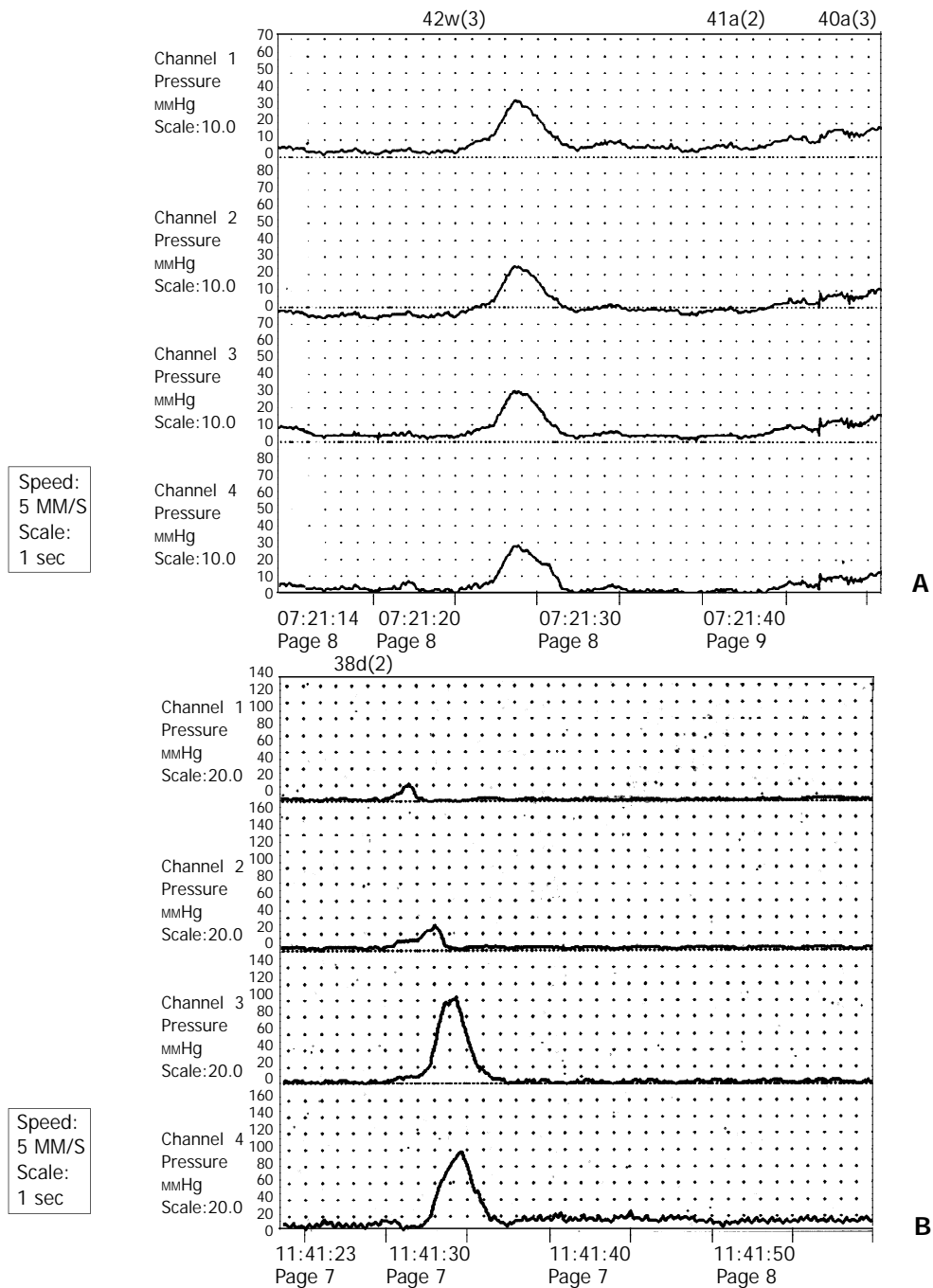


Figure 3 Esophageal manometric tracings obtained from a 29-y female patient with achalasia before and after Heller's myotomy. A, Preoperative manometry showed simultaneous contractions of the esophagus, suggesting no pulsive peristalsis. B, Esophageal manometry revealed peristaltic contractions seven years after Heller's myotomy.

DISCUSSION

Achalasia is an uncommon disease. Although there are no epidemiological data in China, its incidence is one per 100 000 population in Western countries^[13-16]. The major pathophysiological changes of achalasia are aperistalsis of the smooth muscle portion of the esophagus and absent or incomplete relaxation of LES with swallowing. Neuroanatomic data suggest ganglion cell is degenerated in the esophageal myenteric plexus. Although the cause of achalasia is unknown, it has been hypothesized to be related to class II HLA antigen DQw1^[16], and herpes zoster^[17] or measles virus infections^[18]. The finding of antimyenteric neuron antibodies in achalasia patients has shown it is an autoimmune pathogenesis^[19].

In general, aperistalsis of the esophagus in achalasia patients is not reversible after esophageal myotomy. For this reason, its treatment usually aims at the reduction of LES resting pressure. In the currently used methods, medication and dilation have been found to have a certain efficacy, but the duration of dysphagia relief was short^[20,21]. Thus, up to now, myotomy has been the first choice for achalasia. In the present study, both LES resting pressure and clinical score were significantly decreased after Heller's myotomy, and 84.5% of patients had a good or excellent relief of dysphagia. This figure was consistent with other reports^[22,23]. Furthermore, the relief of clinical symptoms was permanent after Heller's myotomy in the present study. In contrast, the effective relief of symptoms has been reported to present in only 15%-30% of patients one year after intra-sphincter injection of botulinum toxin^[3,24], and in 50% of patients one year after pneumatic dilatation^[3].

Our results of esophageal manometry showed that resting pressure of the esophageal body was also decreased along with the drop of LES pressure after esophageal myotomy. This may be resulted from the reduction or disappearance of intra-esophageal content after Heller's myotomy. Generally, aperistaltic esophagus could not become peristaltic after Heller's myotomy. However, we found that aperistaltic esophagus resumed peristalsis in 4 patients at 20 months, 7, 15 and 20 years after surgery, respectively. In these patients, the mean time of dysphagia was 1.1 years (range 2 months to 8 years) before surgery, which was shorter than that in the entire group (4.8 years), and there were 2 patients with moderate dilation of the esophagus and 2 with mild dilation. Although the reason is unknown, this finding indicates that it is potential for a few achalasia patients to resume their esophageal peristalsis after Heller's myotomy. Chen and colleagues^[25] found that the return of peristalsis was seen mainly in patients with a short clinical evolution, and a little esophageal dilation with preserved contractile capacity. Therefore, we suggest that Heller's myotomy should be performed as early as possible once achalasia is diagnosed.

In the present study, DeMeester scores had no significant changes after Heller's myotomy compared with preoperative values. It was reported that gastroesophageal reflux seldom occurred in patients with achalasia before Heller's myotomy, and the reasons for higher DeMeester scores in aperistaltic esophagus were due to the increase of lactic acid resulted from fermentation of retained food in the esophagus^[26,27]. In the present study, 24-hour esophageal pH monitoring showed that DeMeester scores were above the normal level in 33.3% of patients before surgery, which is higher than the incidence in normal populations. After Heller's myotomy, gastroesophageal reflux may occur because of the destruction of anti-reflux barrier. Our results also showed that the overall incidence of gastroesophageal reflux was 45.5% in patients undergoing Heller's myotomy. In the literature, the corresponding figure was 25% in those who had undergone esophageal myotomy in combination with anti-reflux procedure^[28].

In the present study, 3 (1.7%) patients developed squamous cell carcinoma, while the reported incidence varied between

1.7% and 20%^[22,29]. Ribeiro *et al*^[30] indicated that chronic irritation of the esophagus appeared to participate in the process of carcinogenesis in patients with achalasia. Although esophageal emptying has been significantly improved after Heller's myotomy, it could not reach normal level because of the aperistaltic esophagus. For this reason, epithelial hyperplasia of the esophagus caused by chronic irritation before surgery may develop into cancer after surgery. Thus, the incidence of squamous cell carcinoma in achalasia patients who have undergone Heller's myotomy is still higher than that in normal population. For this reason, esophagoscopy should be performed for achalasia patients before surgery and at postoperative follow-up to rule out cancer.

It has been a controversy whether an anti-reflux procedure should be performed with Heller's myotomy^[31]. In the present study, the postoperative incidence of gastroesophageal reflux in patients who underwent Heller's myotomy in combination with antireflux procedure was 27.3% compared to 63.6% in those undergoing Heller's myotomy only. In addition, esophagitis was found in 46.7% of patients at postoperative follow-up, and most of them might be resulted from gastroesophageal reflux. However, there were no significant differences in DeMeester and clinical scores between Heller's myotomy only and myotomy in combination with antireflux procedure. Esophageal bleeding resulted from gastroesophageal reflux occurred in one patient who underwent myotomy alone and severe dysphagia occurred in 2 patients who underwent myotomy in combination with anti-reflux procedure due to scar formation around the abdominal segment of the esophagus. Therefore, there is no overwhelming evidence to indicate myotomy in combination with anti-reflux procedure is better than myotomy only for achalasia, and a large number of patients should be studied randomly before the dispute is settled. In our experience, partial rather than total fundoplication should be performed with myotomy because aperistaltic esophagus has a poor emptying ability, and total fundoplication hinders esophageal transit more severely than partial fundoplication does.

Up to now, modified Heller's myotomy is still the best choice for achalasia because of its high rate of symptom relief and permanent efficacy. Heller's myotomy in combination with antireflux procedure could stop gastroesophageal reflux to a certain extent, but a large number of patients should be studied randomly to further demonstrate its efficacy.

REFERENCES

- 1 **Anselmino M**, Perdakis G, Hinder RA, Polishuk PV, Wilson P, Terry JD, Lanspa SJ. Heller myotomy is superior to dilatation for the treatment of early achalasia. *Arch Surg* 1997; **132**: 233-240
- 2 **Katz PO**, Gilbert J, Castell DO. Pneumatic dilatation is effective long-term treatment for achalasia. *Dig Dis Sci* 1998; **43**: 1973-1977
- 3 **Mikaeli J**, Fazel A, Montazeri G, Yaghoobi M, Malekzadeh R. Randomized controlled trial comparing botulinum toxin injection to pneumatic dilatation for the treatment of achalasia. *Aliment Pharmacol Ther* 2001; **15**: 1389-1396
- 4 **Cuilliere C**, Ducrotte P, Zerbib F, Metman EH, de Looze D, Guillemot F, Hudziak H, Lamouliatte H, Grimaud JC, Ropert A, Dapigny M, Bost R, Lemann M, Bigard Denis P, Auget JL, Galmiche JP, Bruley des Varannes S. Achalasia: outcome of patients treated with intrasphincteric injection of botulinum toxin. *Gut* 1997; **41**: 87-92
- 5 **Pasricha PJ**, Ravich WJ, Hendrix TR, Sostre S, Jones B, Kalloo AN. Treatment of achalasia with intrasphincteric injection of botulinum toxin: A pilot trial. *Ann Intern Med* 1994; **121**: 590-591
- 6 **Spiess AE**, Kahrilas PJ. Treating achalasia: from whalebone to laparoscope. *JAMA* 1998; **280**: 638-642
- 7 **Torbey CF**, Achkar E, Rice TW, Baker M, Richter JE. Long-term outcome of achalasia treatment: the need for closer follow-up. *J Clin Gastroenterol* 1999; **28**: 125-130
- 8 **Eckardt VF**, Aigner C, Bernhardt G. Predictors of outcome in patients with achalasia treated by pneumatic dilation. *Gastroen-*

- terology* 1992; **103**: 1732-1738
- 9 **Liu JF**, Wang QZ, Li WQ, Li BQ, Wang FS, Cao FM, Tian ZQ, Zhang YF. Esophageal scintigraphy to quantitate esophageal transit of the achalasia patients after Heller's myotomy. *Zhonghua Heyixue Zazhi* 1995; **15**: 228-229
 - 10 **Gallone L**, Peri G, Galliera M. Proximal gastric vagotomy and anterior fundoplication as complementary procedures to Heller's operation for achalasia. *Surg Gynecol Obstet* 1982; **155**: 337-341
 - 11 **Bonavina L**, Nosadini A, Bardini R, Baessato M, Peracchia A. Primary treatment of esophageal achalasia. Long-term results of myotomy and Dor fundoplication. *Arch Surg* 1992; **127**: 222-226
 - 12 **Devaney EJ**, Lannettoni MD, Orringer MB, Marshall B. Esophagectomy for achalasia: patient selection and clinical experience. *Ann Thoracic Surg* 2001; **72**: 854-858
 - 13 **Mayberry JF**, Atkinson M. Studies of incidence and prevalence of achalasia in the Nottingham area. *Q J Med* 1985; **56**: 451-456
 - 14 **Earlham RJ**, Ellis FH Jr, Nobrega FT. Achalasia of the esophagus in a small urban community. *May Clin Proc* 1969; **44**: 478-483
 - 15 **Howard PJ**, Maher L, Pryde A, Cameron EW, Heading RC. Five year prospective study of the incidence, clinical features, and diagnosis of achalasia in Edinburgh. *Gut* 1992; **33**: 1011-1015
 - 16 **Wong RK**, Maydonovitch CL, Metz SJ, Baker JR Jr. Significant DQw1 association in achalasia. *Dig Dis Sci* 1989; **34**: 349-352
 - 17 **Robertson CS**, Martin BA, Atkinson M. Varicella-zoster virus DNA in the oesophageal myenteric plexus in achalasia. *Gut* 1993; **34**: 299-302
 - 18 **Jones DB**, Mayberry JF, Rhodes J, Munro J. Preliminary report of an association between measles virus and achalasia. *J Clin Pathol* 1983; **36**: 655-657
 - 19 **Verne GN**, Sallustio JE, Eaker EY. Anti-myenteric neuronal antibodies in patients with achalasia: A prospective study. *Dig Dis Sci* 1997; **42**: 307-313
 - 20 **Gelfond M**, Rozen P, Gilat T. Isosorbide dinitrate and nifedipine treatment of achalasia: a clinical, manometric and radionuclide evaluation. *Gastroenterology* 1982; **83**: 963-969
 - 21 **Traube M**, Hongo M, Magyar L, McCallum RW. Effects of nifedipine in achalasia and in patients with high-amplitude peristaltic esophageal contractions. *JAMA* 1984; **252**: 1733-1736
 - 22 **Shai SE**, Chen CY, Hsu CP, Hsia JY, Yang SS. Transthoracic oesophagomyotomy in the treatment of achalasia--a 15-year experience. *Scand Cardiovasc J* 1999; **33**: 333-336
 - 23 **Ionescu NG**, Pereni O, Maghiar A, Ionescu C, Ionescu S, Maghiar T. Oesophageal: Surgical consideration in the management of achalasia. *Br J Surg* 1995; **82**: 105
 - 24 **Bassotti G**, Annese V. Review article: Pharmacological options in achalasia. *Aliment Pharmacol Ther* 1999; **13**: 1391-1396
 - 25 **Chen LQ**, Chughtai T, Sideris L, Nastos D, Taillefer R, Ferraro P, Duranceau A. Long-term effects of myotomy and partial fundoplication for esophageal achalasia. *Dis Esophagus* 2002; **15**: 171-179
 - 26 **Spechler SJ**, Souza RF, Rosenberg SJ, Ruben RA, Goyal RK. Heartburn in patients with achalasia. *Gut* 1995; **37**: 305-308
 - 27 **Smart HL**, Mayberry JF, Atkinson M. Achalasia following gastro-oesophageal reflux. *J R Soc Med* 1986; **79**: 71-73
 - 28 **Ponce J**, Juan M, Garrigues V, Pascual S, Berenguer J. Efficacy and safety of cardiomyotomy in patients with achalasia after failure of pneumatic dilatation. *Dig Dis Sci* 1999; **44**: 2277-2282
 - 29 **Sandler RS**, Nyren O, Ekblom A, Eisen GM, Yuen J, Josefsson S. The risk of esophageal cancer in patients with achalasia: A population-based study. *JAMA* 1995; **274**: 1359-1362
 - 30 **Ribeiro U Jr**, Posner MC, Safatle-Ribeiro AV, Reynolds JC. Risk factors for squamous cell carcinoma of the oesophagus. *Br J Surg* 1996; **83**: 1174-1185
 - 31 **Cosentini E**, Berlakovich G, Zacherl J, Stacher-Janotta G, Merio R, Wenzl E, Bergmann H, Stacher G. Achalasia. Results of myotomy and antireflux operation after failed dilatations. *Arch Surg* 1997; **132**: 143-147

Edited by Wang XL Proofread by Zhu LH